DISEASE AND HEALTH MANAGEMENT - POULTRY

ASCI 250

Dr. Sheila Purdum

Types of Disease in Poultry

- Bacterial
- Viral
- Fungal
- Parasitic
- Nutritional Deficiencies

Bacterial Diseases

- Coliform bacillosis
- Yolk sac infections
- Necrotic Enteritis
- Fowl Cholera
- Salmonellosis
- Tuberculosis

Fowl Cholera

- Can come from migrating waterfowl

Fowl cholera (*Pasteurella multocida*)

16

16 Swollen wattles in a male broiler breeder due to *P. multocida* infection. The affected males may be slightly depressed in localised infection of this type. Swollen wattles may also occur amongst the females, as well as a cellulitis, which is usually seen over the head and neck. Otitis, with the appearance of exudate at the external ear opening, is less common.

17

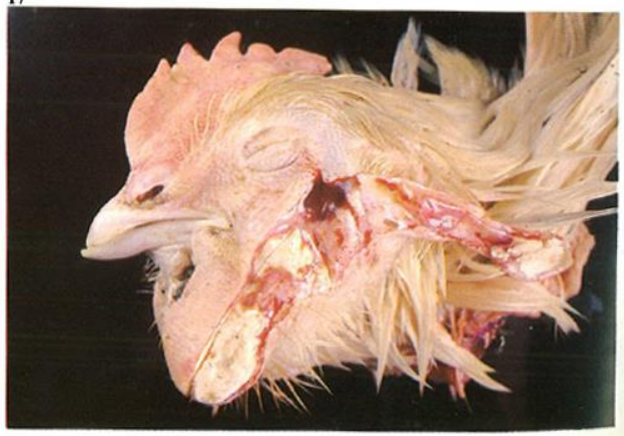

17 Core of purulent material in a swollen wattle of a broiler breeder hen. *P. multocida* can be isolated from most acute lesions of this type but only rarely from chronic abscesses. This may give rise to some diagnostic difficulty as wattle abscesses can be caused by a variety of bacteria.

Tuberculosis

- Mostly in free-range birds

Tuberculosis (*Mycobacterium avium*)

71 The disease is common in free-range fowl but seen only rarely under intensive systems of husbandry. Affected birds gradually become emaciated, and yellowish caseous nodules are most commonly found in the liver, spleen and intestine. Well-developed lesions in the liver can usually be shelled out from the surrounding parenchyma.

71

Salmonellosis

- Many strains: Salmonella pullorum (eradicated in most states due to NPIP program.
- Salmonella Typhimurium
- Salmonella Enteriditis (food borne illness in eggs) vaccine is now available

Salmonellosis

This section refers only to diseased birds. Many birds may be infected with salmonellas and show no clinical or post-mortem signs. As used here, the term 'salmonellosis' refers also to the now rare diseases caused by *Salmonella pullorum* and *S. gallinarum*.

79 *S. typhimurium*. Gross lesions are very variable. Heavy mortality may result in young chicks and turkey poults. Focal lesions are present in the liver of this 7-day-old broiler.

79

Mycoplasmosis

- Severe respiratory infection in turkeys

92 *Mycoplasma gallisepticum*. Swelling of the infraorbital sinuses in a turkey.

92



93 *M. gallisepticum*. Infraorbital sinus of a turkey opened to show sticky exudate in an acute case.

93

Viral Diseases

- Infectious Bursal Disease
- Fowl Pox
- Infectious Laryngotracheitis
- Newcastle Disease
- Mareks disease (transient paralysis)
- Lymphoid Leukoses

Infectious Bursal Disease

- Bursa is important for production of immunoglobulins in response to vaccines, this disease severely inhibits immune function in young poultry

113 A large mass of purulent exudate in the lumen of the bursa of Fabricius. Note the longitudinal surface indentations in this material caused by the plical folds of the bursa. The kidneys of this broiler are jaundiced, death having resulted from inclusion body hepatitis (*see* **123**). The bursal lesions were caused by an earlier challenge with the infectious bursal disease agent.

113

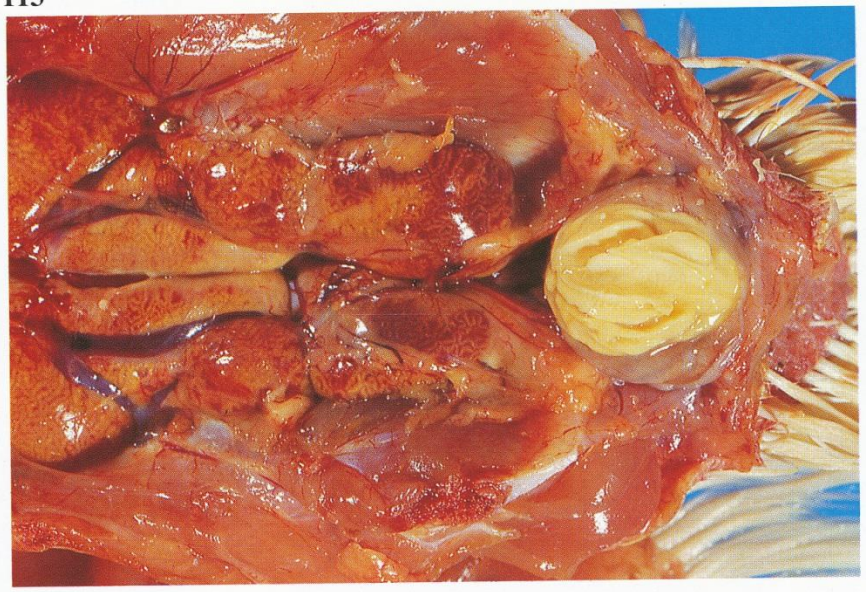

Fowl Pox

- Similar virus to Chicken pox in humans, but different strain and not transmissible

Fowl pox

130 The disease may affect both chickens and turkeys and can cause cutaneous and internal lesions. Here, pox lesions are present in the oropharynx of a hen.

130

Infectious bronchitis

- Abnormal shells due to disruption of CO2 flow to shell gland

150 A wide range of egg abnormalities may be observed if susceptible laying fowl are infected. Shells are often ridged or have concretions on their surface, or they may be misshapen in other ways, as here.

150



Mareks Disease

- Transient paralysis dud to abnormal sciatic nerve

Marek's disease (including transient paralysis)

171 Paresis of the right leg. If both legs are involved, a characteristic posture is often assumed, with one leg pointing forwards and the other held backwards under the body.

171

Fungal Disease

- Aspergillosis
- Candidiasis

Aspergillosis

224 The disease is common in chicks and turkey poults during the first week or so of life and usually arises from contact with contaminated litter. If the infection is acquired in the hatchery – a rare event these days – pneumonia can develop by 2 days of age. Occasionally, lesions are confined to the bronchi and are not observed unless the lung is cut through. The miliary lesions seen here are in the lung of a 9-week-old pheasant.

224

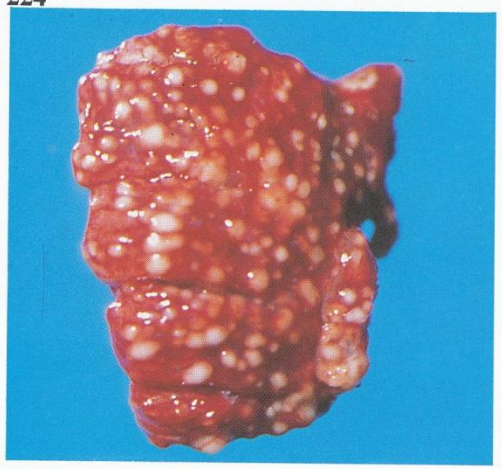

Parasitic Challenges

- Coccidiosis
- Histomoniasis
- Lice
- Northern Fowl Mite
- Ascardis

Coccidiosis Cycle in Poultry (occurs in other livestock too)

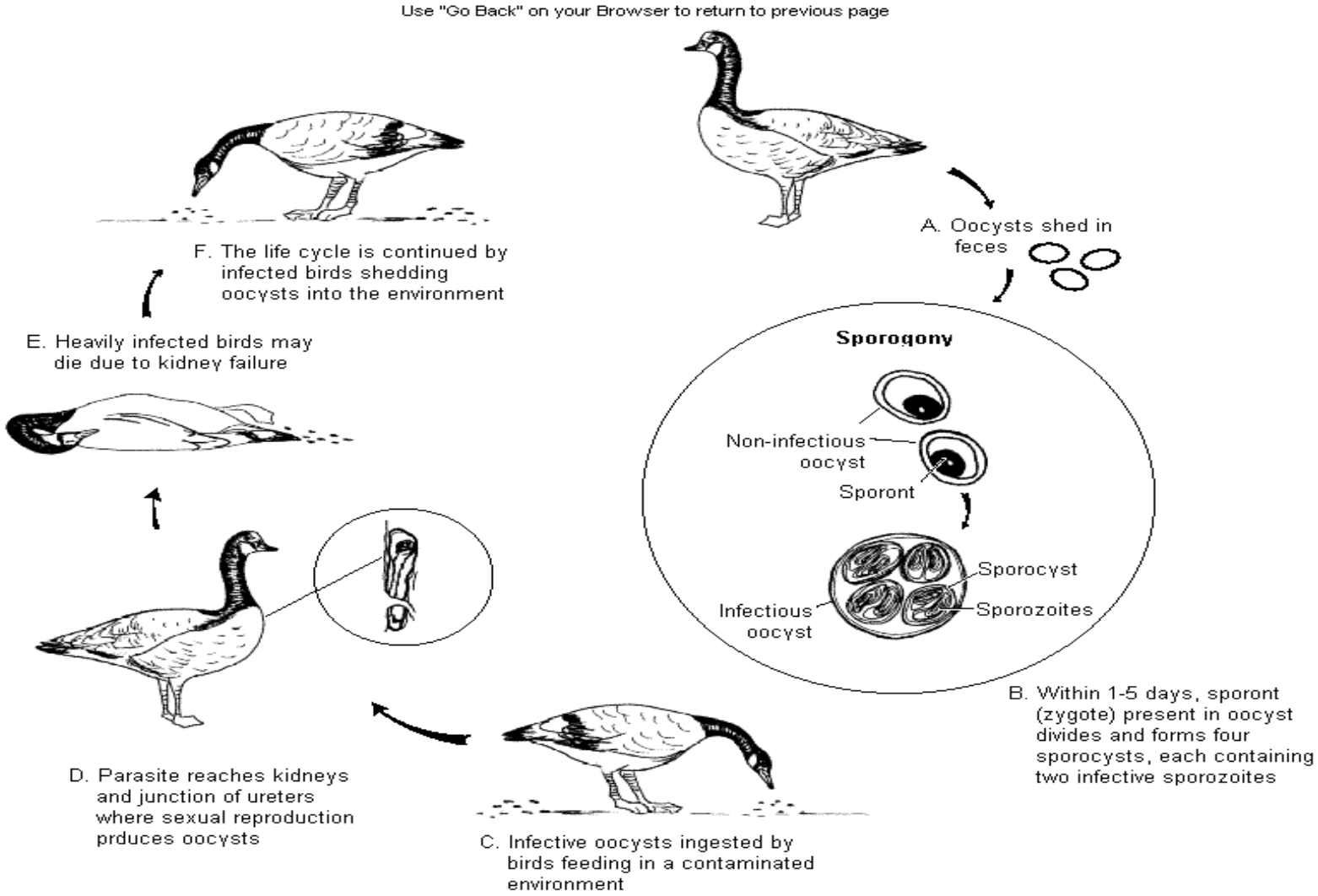

Life cycle of Eimeria truncata, which is one of the parasites that causes renal coccidiosis

Parasites - Worms

- Dewormers such as Ivermectin work for poultry

Ascaridiasis

239 The heavy infestation with *Ascaridia galli* shown here is not common under intensive systems of husbandry, except in the presence of a disease such as Marek's. Light-to-moderate worm burdens are encountered more frequently.

239

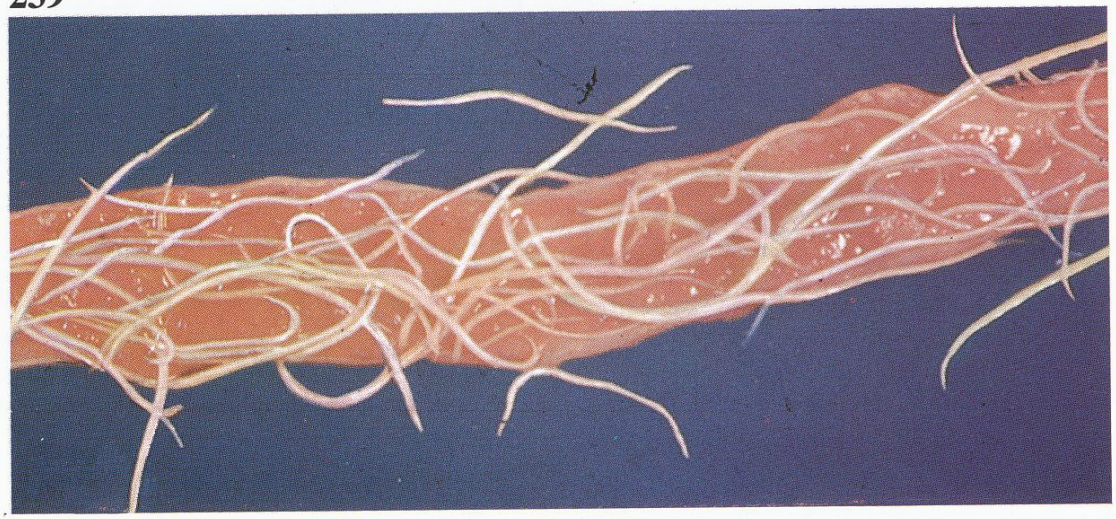

Severe Lice Infection

- Must kill by contact with an insecticide such a “Sevin” type of dust and must clean from premises (likely in nest bedding materials)



Lice

265 Large numbers of eggs (species unidentified) on feathers of a laying fowl from a flock where egg production was poor.

265

Northern Fowl Mites

- Can jump from from wild birds

Northern fowl mite (*Ornithonyssus sylviarum*)

268 These live continuously upon the birds, and are seen here on the feathers of a broiler breeder that was submitted with excoriated tail and vent skin. The mites move quickly and are easily transferred to the gloves and arms of the person doing the post-mortem examination.

268

Vaccination Programs

- Hatchery – both in ovo and after hatch
  - Newcastle
  - Mareks
  - Bursal Disease
  - Coccidiosis
- Pullet Rearing
  - Salmonella
  - E-Coli
  - Newcastle
  - Bronchitis
  - Fowl Pox
  - Laryngotracheitis

Biosecurity

- http://www.aphis.usda.gov/animal_health/birdbiosecurity/

- NPIP – National Poultry Improvement Plan – monitors bird disease at a National level with representatives in each state
  - In Nebraska – coordinated by the Nebraska Dept. of Agriculture, State Veterinarian